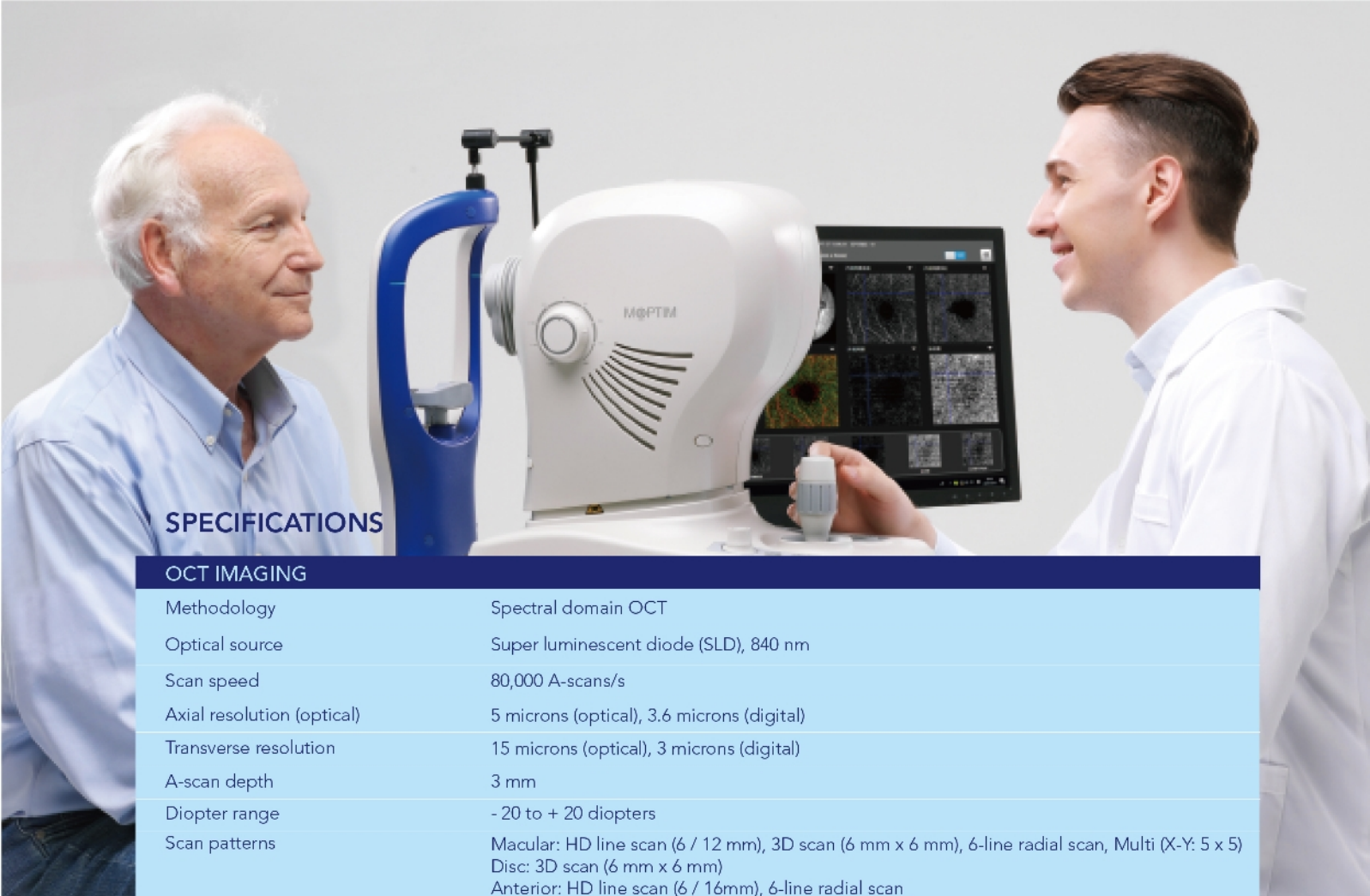



## SPECIFICATIONS

### OCT IMAGING

Methodology	Spectral domain OCT
Optical source	Super luminescent diode (SLD), 840 nm
Scan speed	80,000 A-scans/s
Axial resolution (optical)	5 microns (optical), 3.6 microns (digital)
Transverse resolution	15 microns (optical), 3 microns (digital)
A-scan depth	3 mm
Diopter range	- 20 to + 20 diopters
Scan patterns	Macular: HD line scan (6 / 12 mm), 3D scan (6 mm x 6 mm), 6-line radial scan, Multi (X-Y: 5 x 5) Disc: 3D scan (6 mm x 6 mm) Anterior: HD line scan (6 / 16mm), 6-line radial scan

### FUNDUS IMAGING

Methodology	Line scanning laser ophthalmoscopy (LSLO)
Minimum pupil diameter	3.0 mm
Field of view	45 degrees

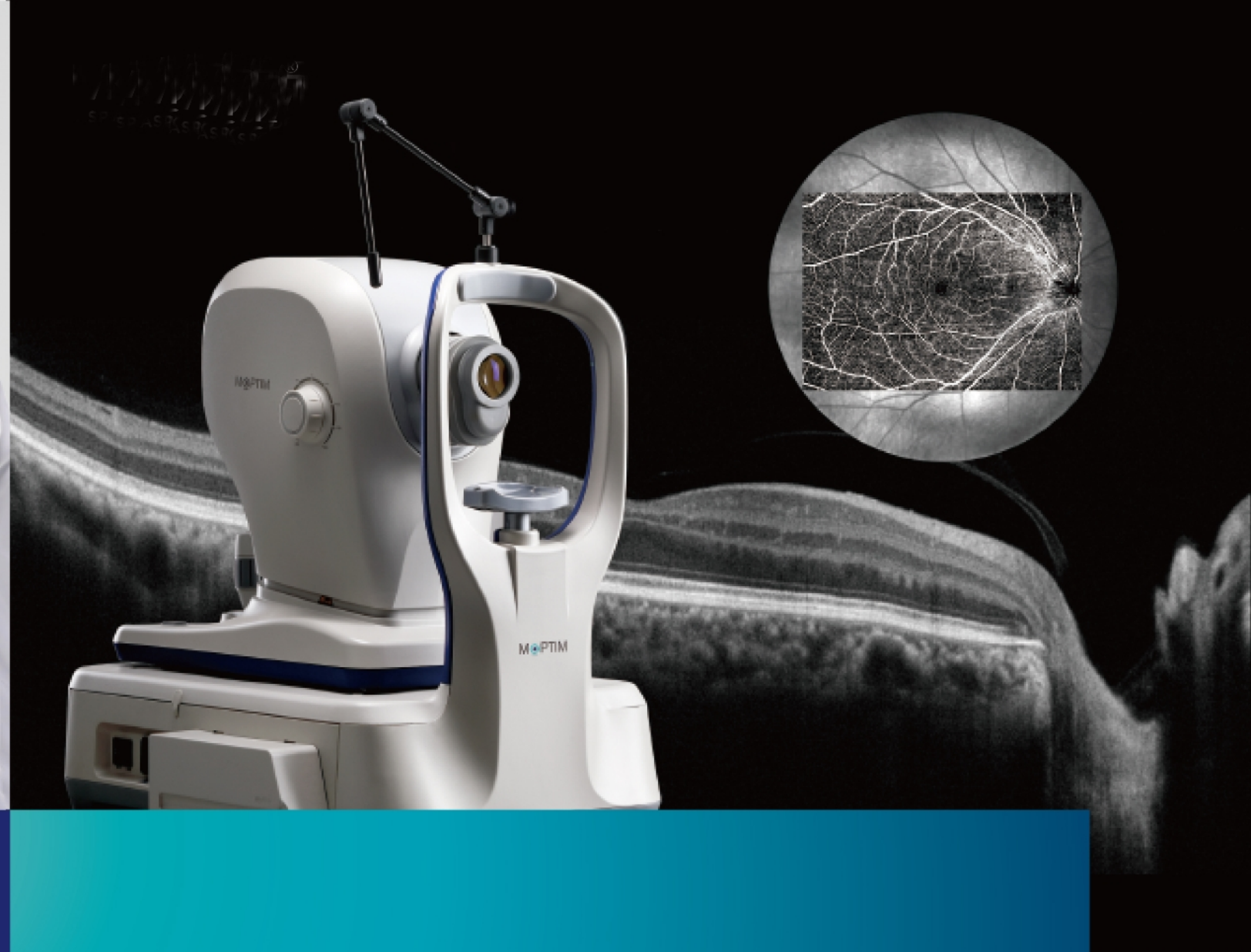### VASCAN™ OCTA MODULE

Scanning volume/area	VASCAN Advance		VASCAN Essential	
	3mm x 3mm	256 x 256 A-scans	3mm x 3mm	256 x 256 A-scans
6mm x 6mm	360 x 360 A-scans	12mm x 8 mm	540 x 360 A-scans	
8mm x 8mm	360 x 360 A-scans			
12mm x 8 mm	540 x 360 A-scans			
Algorithm	C-OMAG		C-OMAG	
Segmentation options	Encoded, Vitreousretina Interface(VRI), Superficial retina, Deepficial retinal, Avascular, Choriocapillaris, Choriod, Custom			
Quantitative analysis	Yes		Not available	

### ELECTRICAL AND PHYSICAL

Weight	30.5 kg
Dimension	532 mm (L) x 360 mm (W) x 540 mm (H)
Source voltage	AC 100 - 240 V, 50 Hz - 60 Hz
Power input	90 VA

Specifications subject to change without notice.



## Optical Coherence Tomography

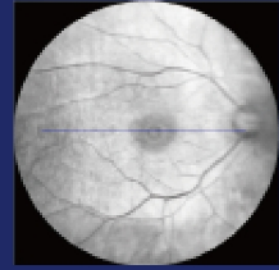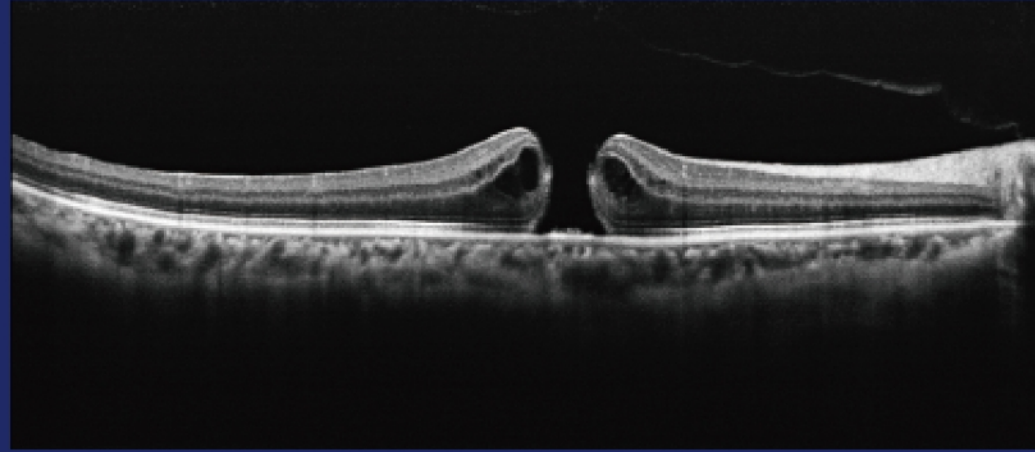
NEW  
eye tracking  
& OCTA

**Mscean® 4000 SLO-OCT**  
with VASCAN OCT Angiography



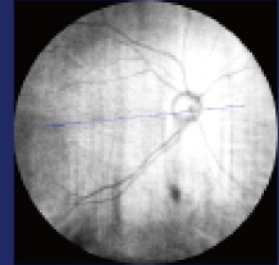
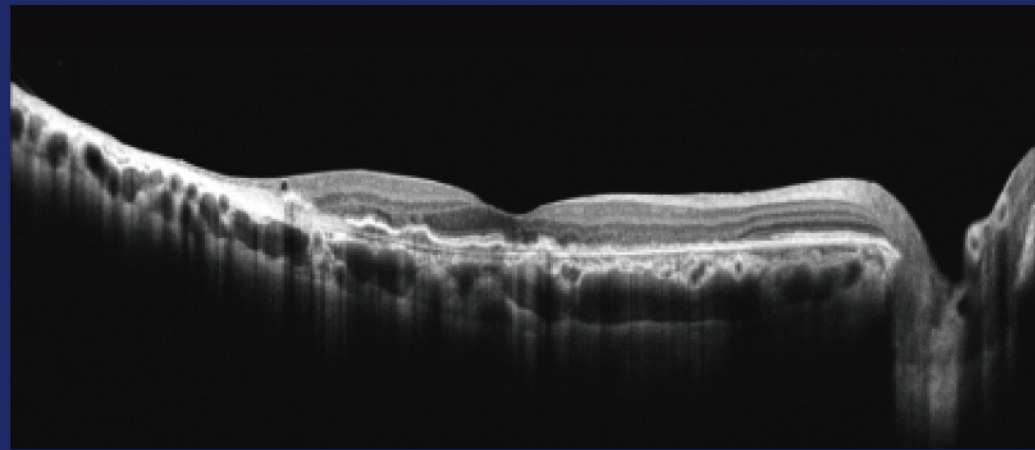
# CLINICAL IMAGE COLLECTION

Macular Hole



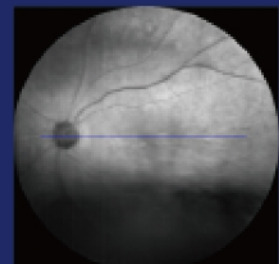
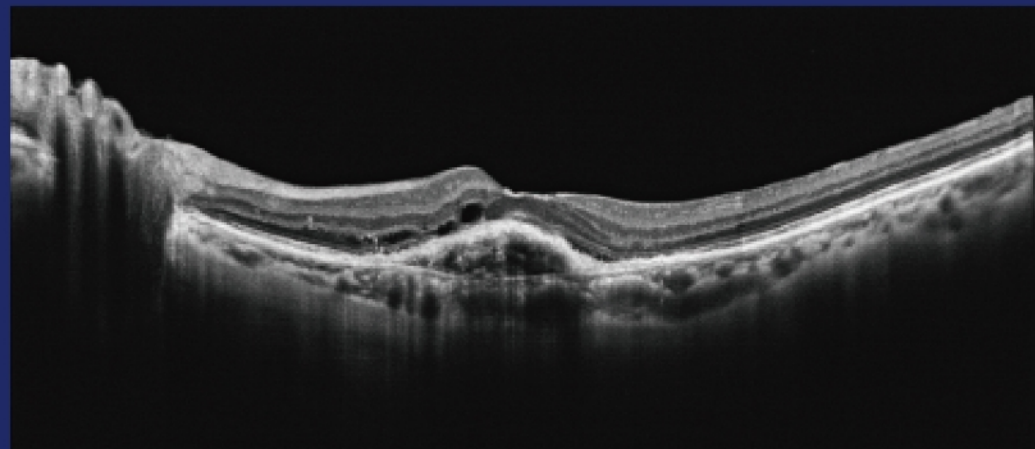
Complete posterior vitreous detachment and hyporeflective intraretinal cysts.

Dry AMD



Several RPE elevations in macula and temporal retinal atrophy.

Wet AMD

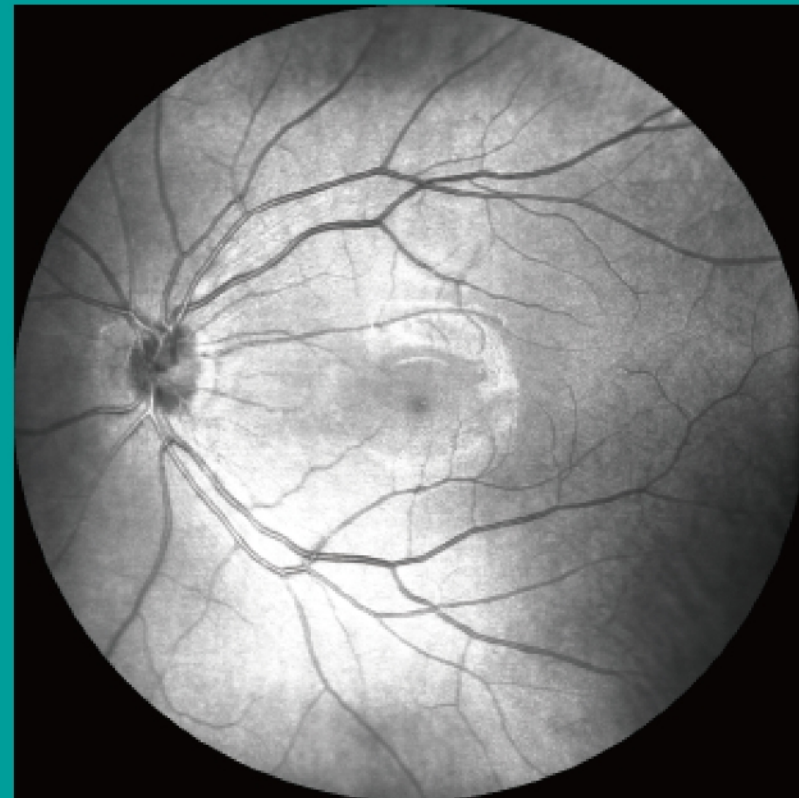

The RPE is discontinuous, and focal moderate-to-high reflectivity in PED can be seen. Cystoid retinal edema with subretinal fluid is on the lesion.

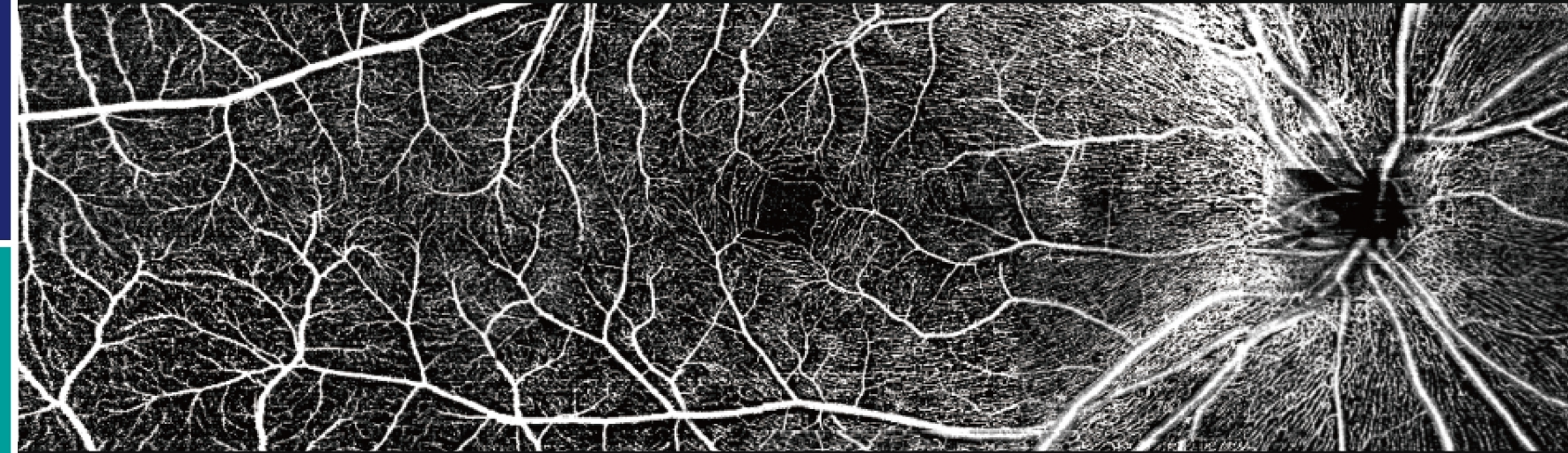
## SUPERIORITY DUE TO ORIGIN

### HD SLO + EYE TRACKING NEW

- 45° wide range live SLO imaging
- Ultra fine quality retinal imaging using averaging technique (up to 50 images)
- SLO-based real-time retinal tracking effectively reduces artifacts caused by eye movement

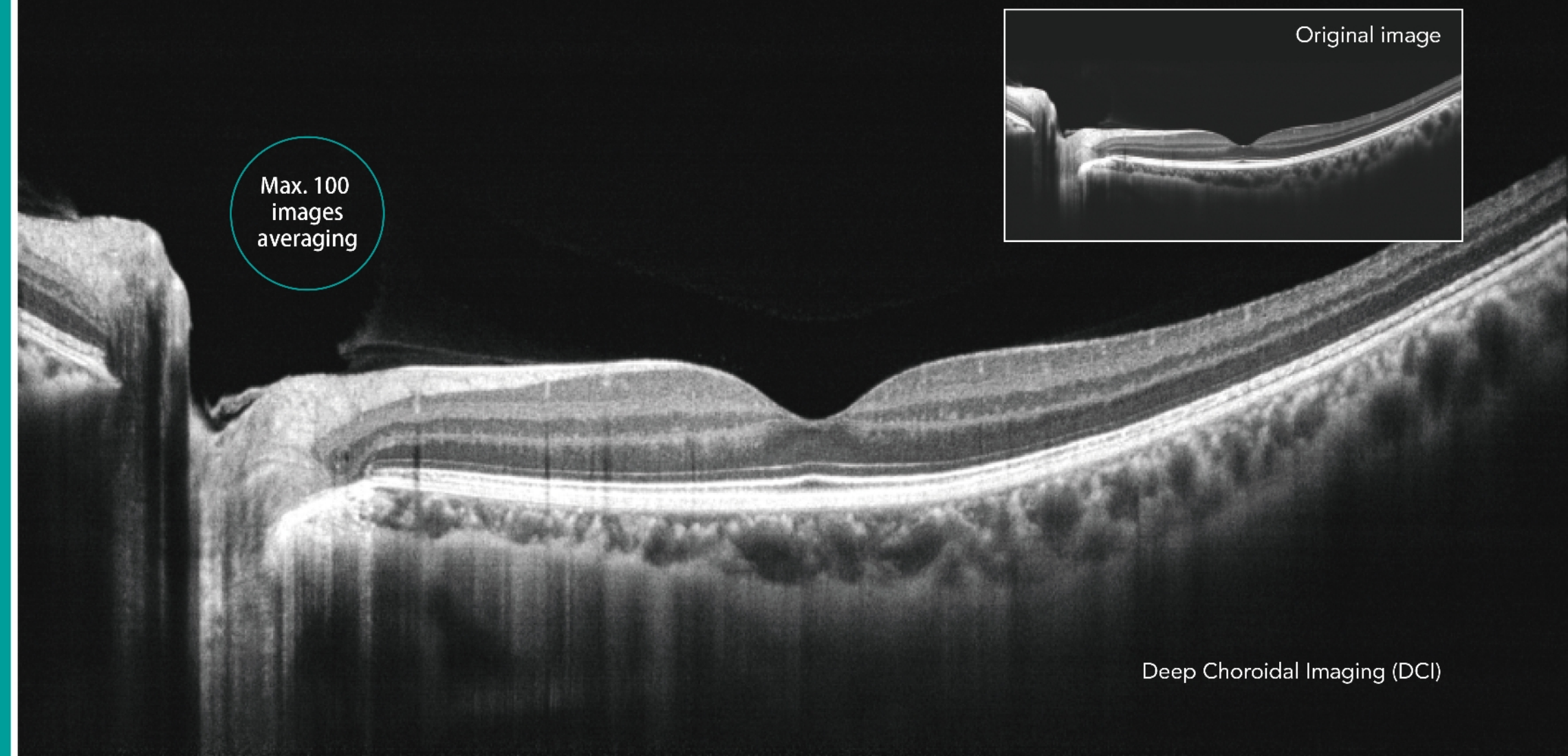


Real-time widefield SLO image

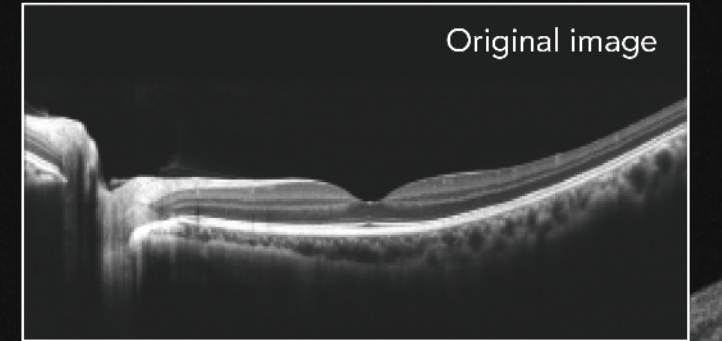


\* Requires optional OCTA license

### HD OCT IMAGING SYSTEM AT 80,000 A-SCANS/S



Max. 100 images averaging



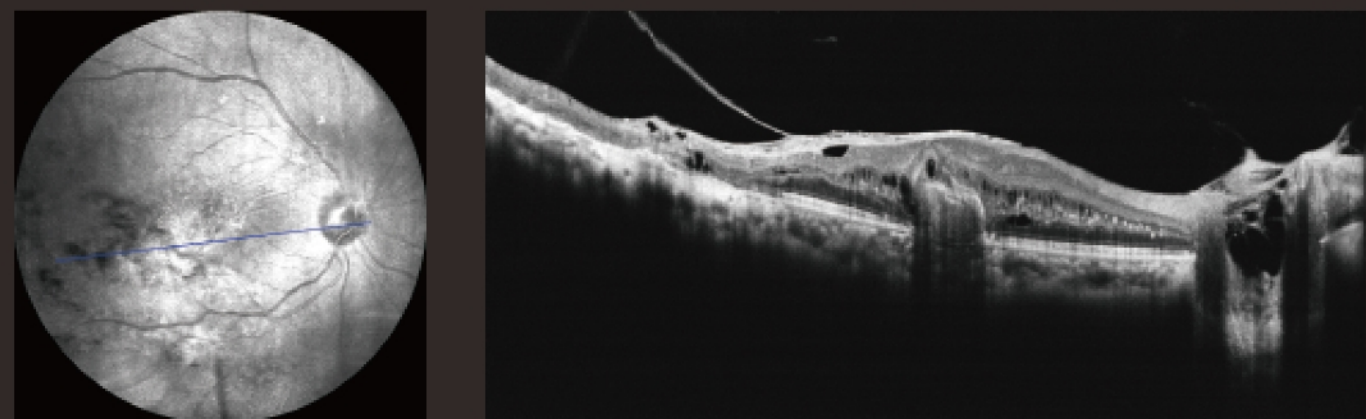
Original image

Deep Choroidal Imaging (DCI)

# MACULA

## Macula HD line

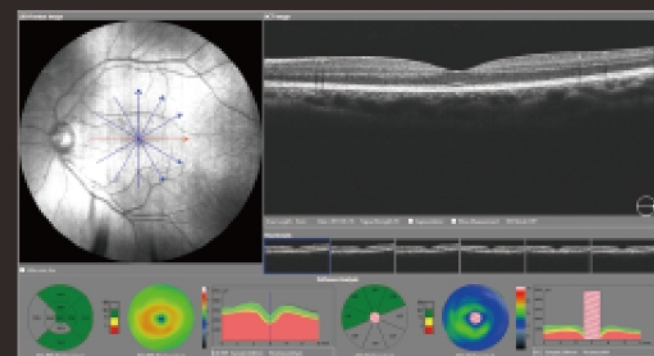
High definition OCT imaging reveals hidden pathological changes



\* OCT scan range can be switched between 6 mm and 12 mm

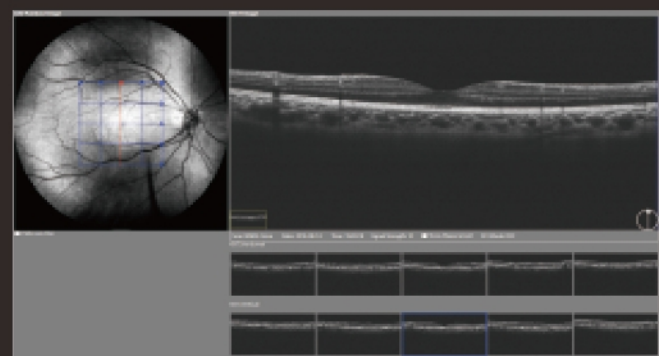
## Macula Six-line Radial

Have a glimpse of the retina via HD imaging and quick data analysis



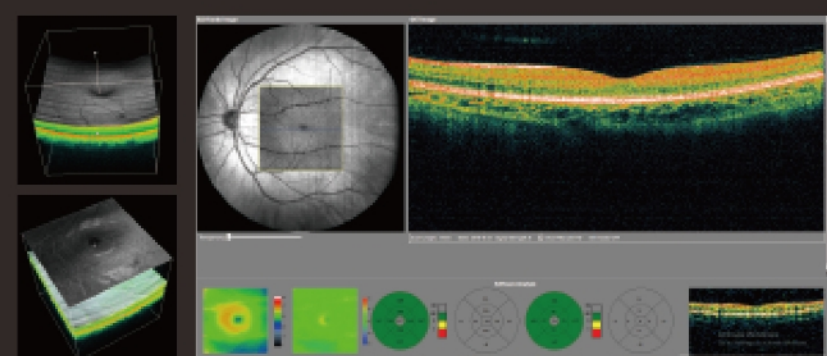
## Macula Multi NEW

Multiple HD cross-sectional images acquisition



## Macula Cube

A point-by-point assessment of retinal thickness with a 500 x 100 dense cube



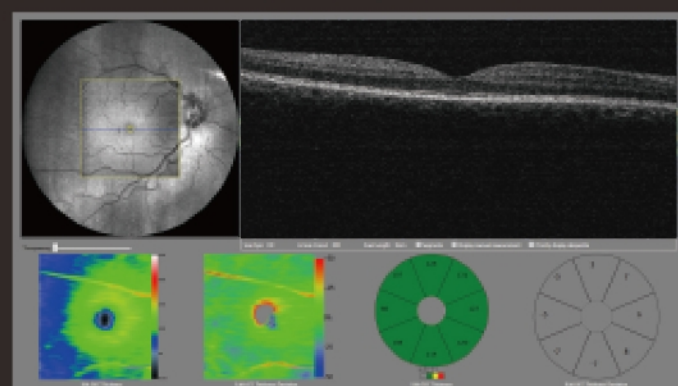
### Software Analysis

- Retinal thickness analysis
- Retinal volume analysis
- Progression analysis
- 3D view
- En-face analysis

# GLAUCOMA

For comprehensive glaucoma analysis, Mocean 4000 offers two scan patterns, glaucoma cube scan in macular area and glaucoma cube scan in disc area. Evenly distributed sampling point with 200 x 200 A-scans provides reliable information for early glaucoma detection and management.

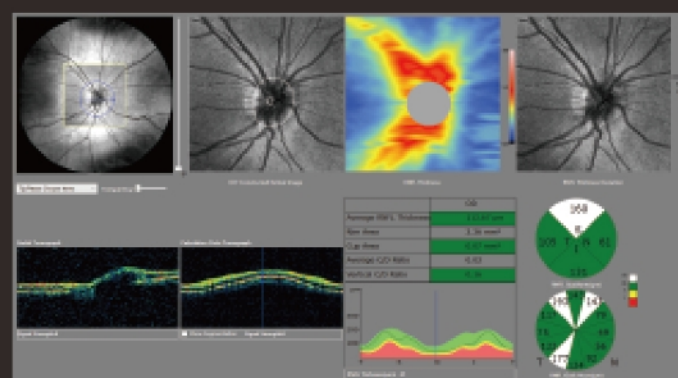
## Glaucoma (Macular)



### Software Analysis

- Ganglion cell analysis
- Progression analysis

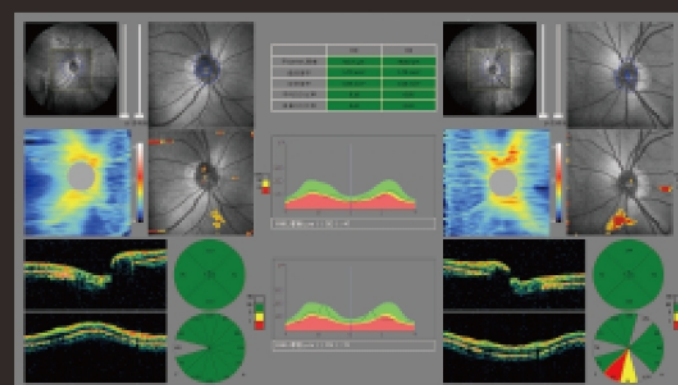
## Glaucoma (Disc)



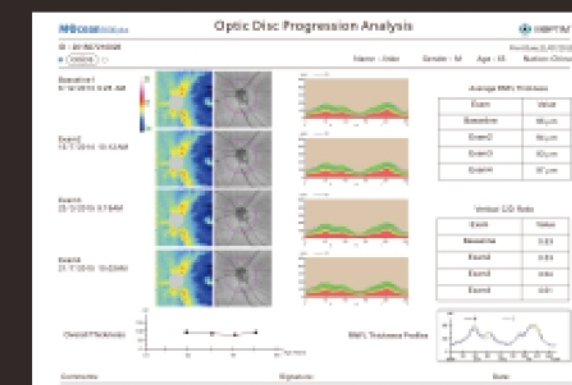
### Software Analysis

- RNFL analysis
- Cup-disk analysis
- Calculation circle and circle scan tomogram
- Progression analysis
- OU comparative analysis

## Informative Report



OU comparative analysis

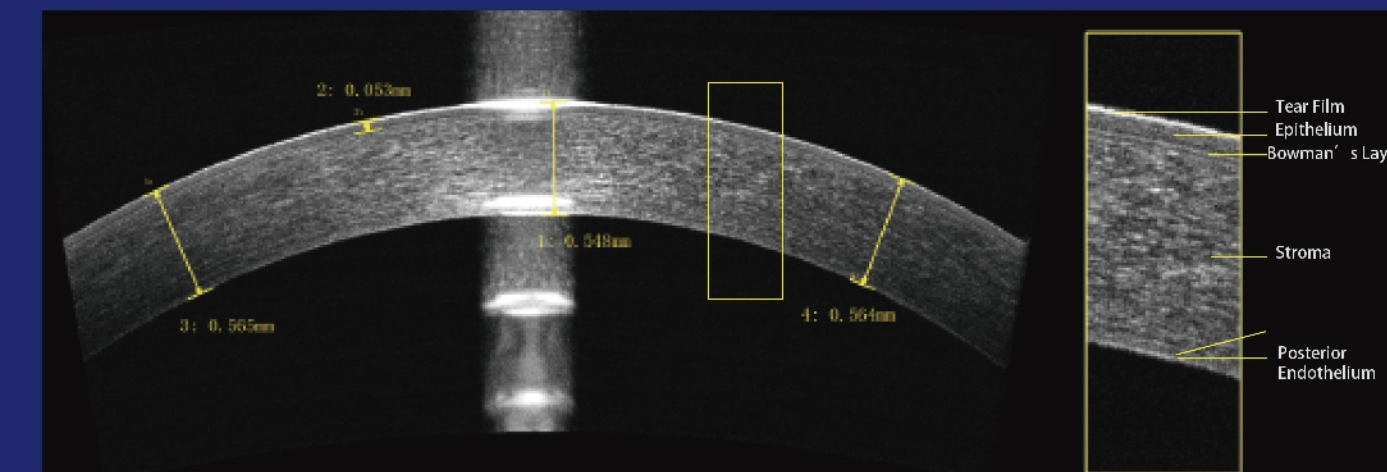


Progression analysis report

# ANTERIOR SEGMENT

## Anterior HD line

High definition OCT imaging of the cornea enables localization of the Bowman's layer, the interface between corneal stroma and epithelium

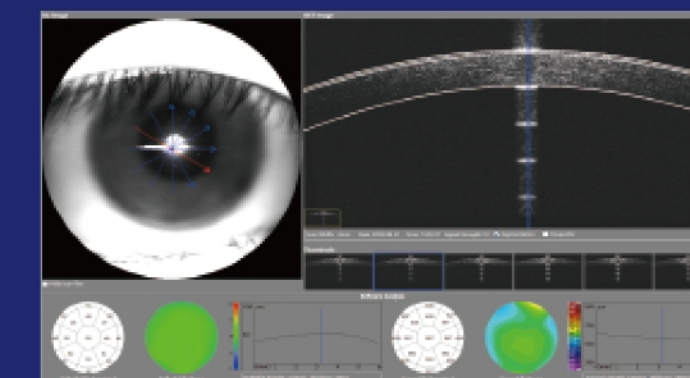


16mm Angle-to-angle scan NEW



## Anterior Six-line Radial

The anterior segment scanning through 6 radial lines of equal length can be used to measure the central corneal thickness



### Software Analysis


- Corneal thickness analysis
- Manual measurement
- Epithelial thickness analysis

NEW

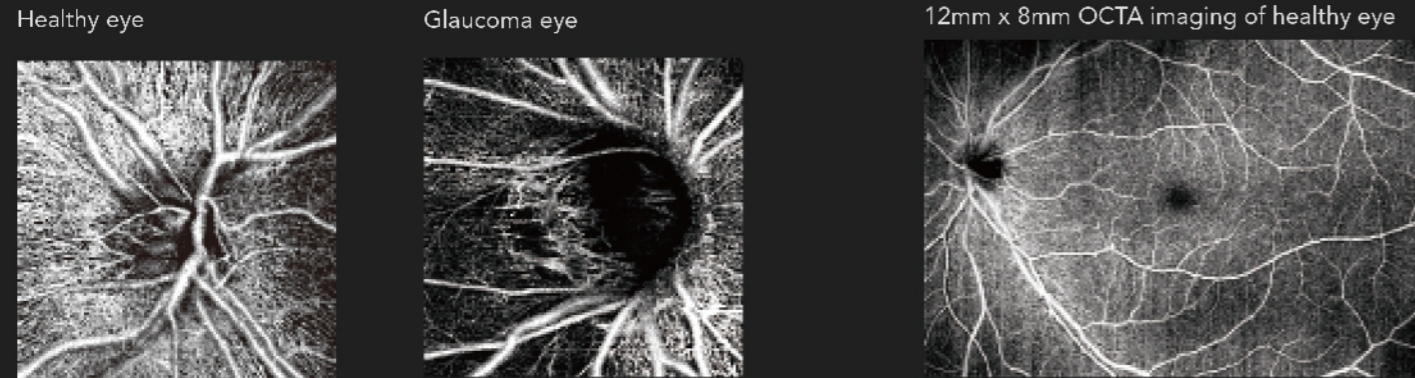## Valuable OCTA for routine clinical practice

Optical Coherence Tomography Angiography (OCTA) is a new non-invasive imaging technique that allows the detailed study of flow within the vascular structure of the eye without the need of dye injections.

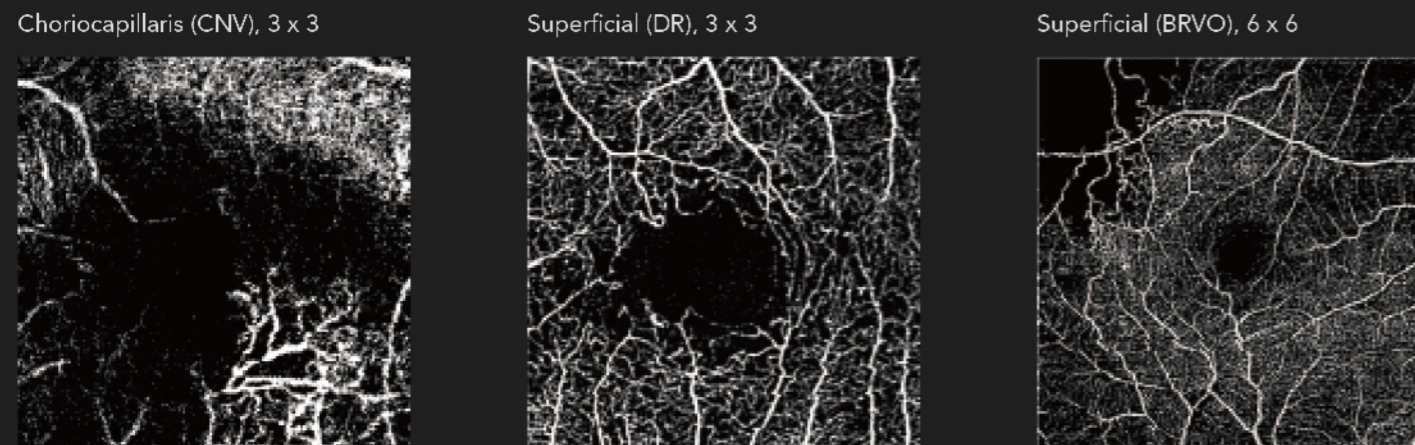
### En face flow images of segmented layers



### OCT Angiography of the Optic Disc

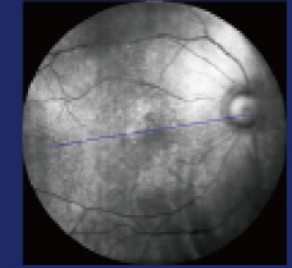
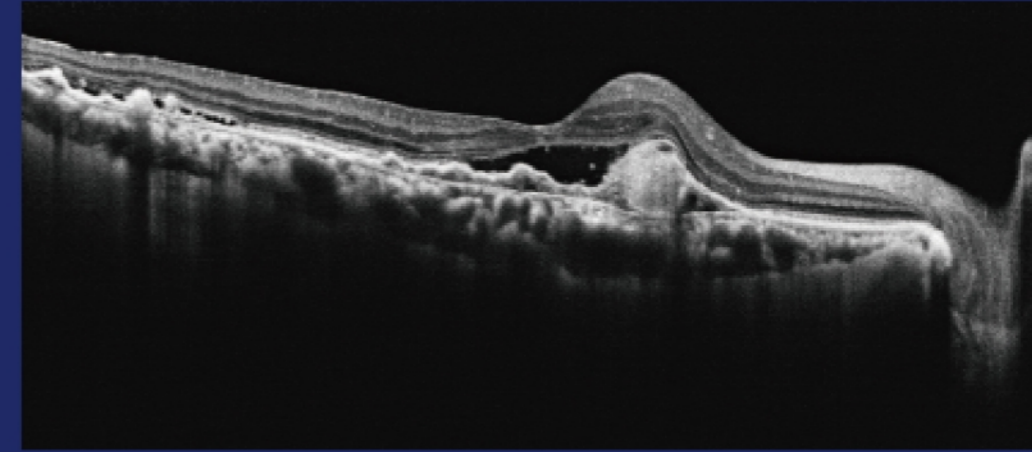


### CLINICAL CASES



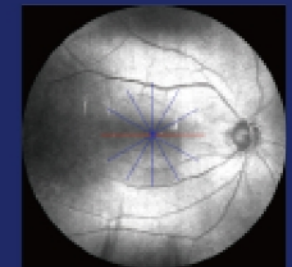
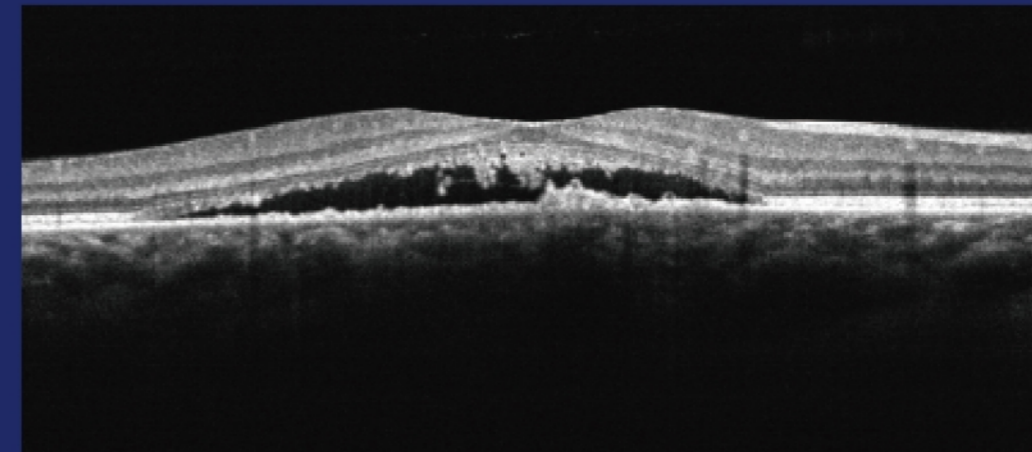
Clinical images courtesy of Peking University Shenzhen Hospital

### Polypoidal choroidal vasculopathy (PCV)



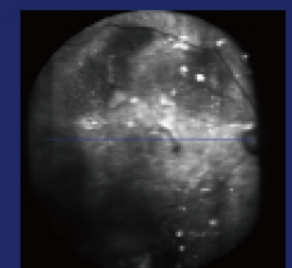
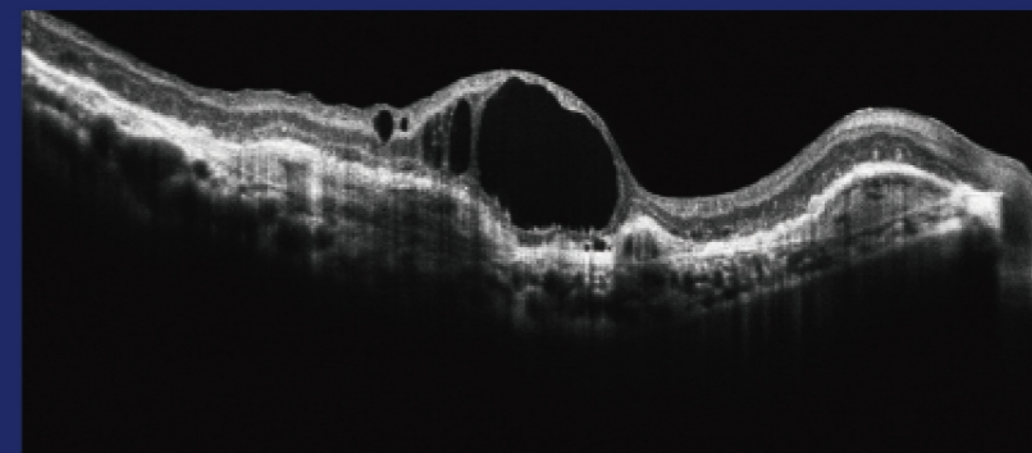
OCT shows dome-shaped PED with a polypoidal lesion inside, which appears as round mild-to-moderate reflective lumen and moderate-to-high reflective wall. Double layer sign is present in the area of macular and temporally. There is subretinal fluid with several punctate hyperreflectivity.

### Central Serous Chorioretinopathy (CSC)



Serous neural retinal detachment in the macula with a mass of granular and stalactite-like moderate-to-high reflectivity in the posterior layer of neural retina.

### Diabetic Retinopathy (DR)



Cystoid macular edema. Several cysts and disordered retinal structure are seen.

Clinical images courtesy of Peking Union Medical College Hospital